

THE CUTTING EDGE

This quarterly column is compiled by JCO Technology Editor W. Ronald Redmond, DDS, MS. To help keep our readers on The Cutting Edge, Dr. Redmond will spotlight a particular area of orthodontic technology every few months. Your suggestions for future subjects or authors are welcome.

This month's column comes from Drs. Francesco Garino and Battista Garino of Turin, Italy. It's a timely look at the paradigm shift in orthodontics from physical impressions to digital representations produced by intraoral scanners. This follows on the heels of the acceptance by the AAO of Invisalign as a method of straightening teeth. Since orthodontists can expect increased patient demand for aligner treatment, the potential improvement in practice efficiency from the use of an iOC scanner becomes even more significant.

In the hands of professionals, new technology quickly expands its potential. Besides the applications described in this paper, my orthodontic colleagues are reporting the fabrication of retainers, Herbst and other laboratory-produced appliances, and setups for indirect bonding by means of stereolithographic model production. The iOC scanner's DICOM data can be converted to an .sla file and easily transmitted to a laboratory for production of a working model. This file conversion involves a nominal fee (currently \$5), but I'm certain the laboratory costs will drop quickly as demand increases.

The latest innovation for the iOC scanner is software, just announced by Align Technology, that will allow patients to view the simulated alignment of their teeth at the chair, immediately following a scan. Continuing my horse-race analogy from previous Cutting Edge introductions, it appears that the intraoral scanners are pulling into the lead, and only a last-minute surge by the cone-beam computed tomography group will make this a close finish.

WRR

The iOC Intraoral Scanner and Invisalign: A New Paradigm

We began using the iOC iTero* intraoral scanner in July 2010, initially to produce digital models, virtual setups, and indirect-bonding trays for adult patients.¹ We are now using the scanner to produce digital models for all our patients,² thus realizing our long-term goal of fully digitizing office procedures and eliminating polyvinyl siloxane (PVS) and alginate impressions.³

In May 2011, Align Technology introduced a process by which records for Invisalign** cases could be submitted using digital models from the iTero scanner instead of PVS impressions. This

*Trademark of Cadent, Inc., Carlstadt, NJ; www.cadent.biz.

**Registered trademark of Align Technology, San Jose, CA; www.aligntech.com.



Dr. F. Garino



Dr. B. Garino

The authors are in the private practice of orthodontics at Corso Matteotti 0, Turin 10121, Italy. E-mail Dr. Francesco Garino at info@drgarino.it.

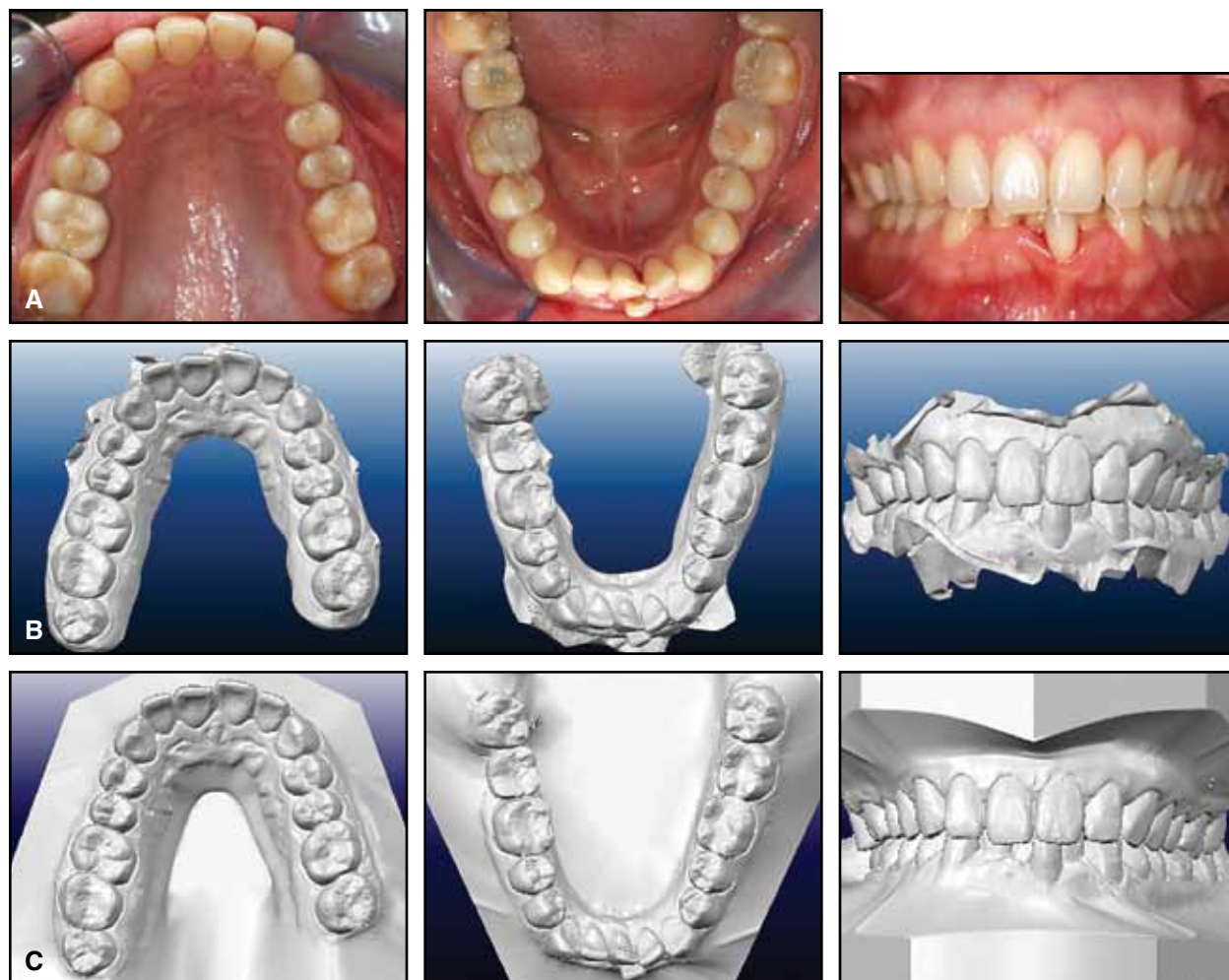


Fig. 1 Pretreatment intraoral photos (A), iRecords (B), and iCasts (C) of 39-year-old female patient with Class I malocclusion, severe deep bite, and lower crowding. Note detail captured by iOC iTero* scanner in interdental areas of overlapping lower central incisors.

article describes the benefits we have observed for the clinician, staff, and patient.

Integration with Invisalign

The integration of iOC with Invisalign represents an important step in the application of digital scanning within the orthodontic practice. The scans produce a virtual impression of the dental arches, which, together with other digital records, are used to prepare a treatment plan, obtain a ClinCheck** virtual setup, and fabricate the aligners. All these procedures are done virtu-

ally over the Internet, obviating the need to package and ship a PVS impression to Align.^{4,6}

After a training period of one to two days—or even less for clinicians who are already using the iOC—the scanning time required is almost the same as for standard digital models. Scanning for Invisalign cases does require extreme accuracy in capturing the interdental contact points, however, especially those of crowded or overlapping

*Trademark of Cadent, Inc., Carlstadt, NJ; www.cadent.biz.

**Registered trademark of Align Technology, San Jose, CA; www.aligntech.com.

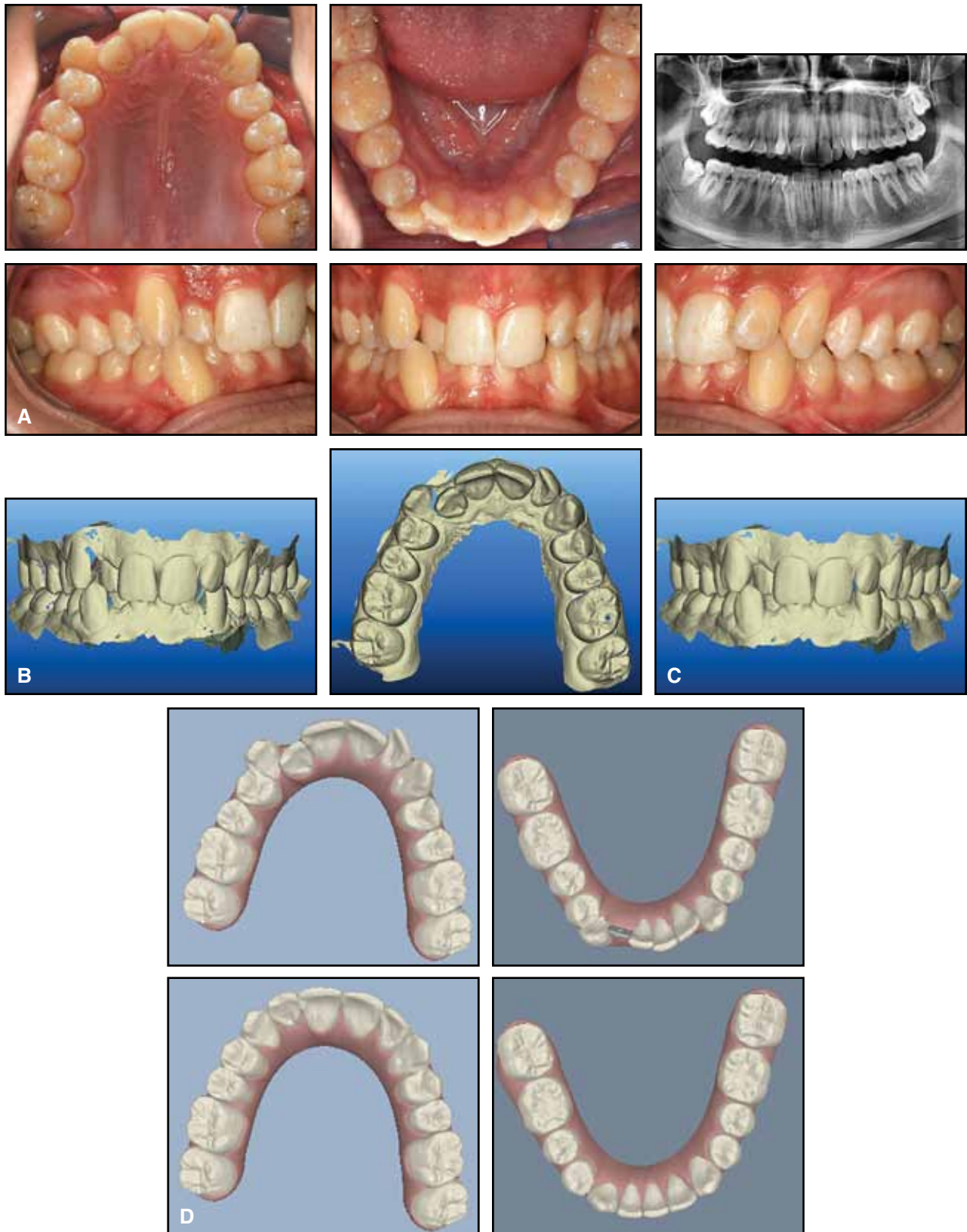


Fig. 2 A. 28-year-old male patient with severe dentoalveolar discrepancy, anterior crowding, and labially displaced canines before treatment. **B.** Blue spots indicate regions where additional scanning is needed. **C.** Further scanning, especially in regions of dental overlap, produces acceptable data. **D.** Pretreatment (top) and projected post-treatment (bottom) ClinCheck** images.

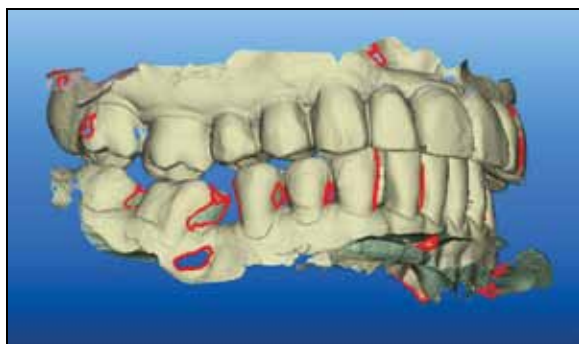

Fig. 3 New version of iOC software highlights missing data with red circles.

anterior teeth, and the palatal and vestibular surfaces of the molars. Correct positioning of the scanning wand is vital to ensure a high-quality scan with adequate detail.

From May to December 2011, we submitted more than 100 Invisalign cases, equally divided between new cases and case refinement, and had no intraoral scans rejected. Our 10 months' experience with the iOC scanner was probably helpful in this regard.

In a malocclusion with severe lower anterior crowding and overlapping incisors (Fig. 1), the scanned results are more detailed and accurate than can be produced with PVS impressions, which must often be retaken due to distortion. The detail of the digital scan improves the fit of the aligners, since the .stl model is made from a nearly perfect registration. In addition, attachments can be placed more accurately using a distortion-free image of the tooth surface.

Scanning Procedure

Our scanner is located in a dedicated room, close to the orthodontic chair. The procedure requires only one operator. A scan usually starts in the left mandibular quadrant, with the operator moving the wand from posterior to anterior, then continues with the right mandibular quadrant. After both arches have been scanned, the session concludes with a bite registration. The sequence can be customized by the operator as desired; a “continuous” scanning mode can be programmed for expert doctors or staff members.

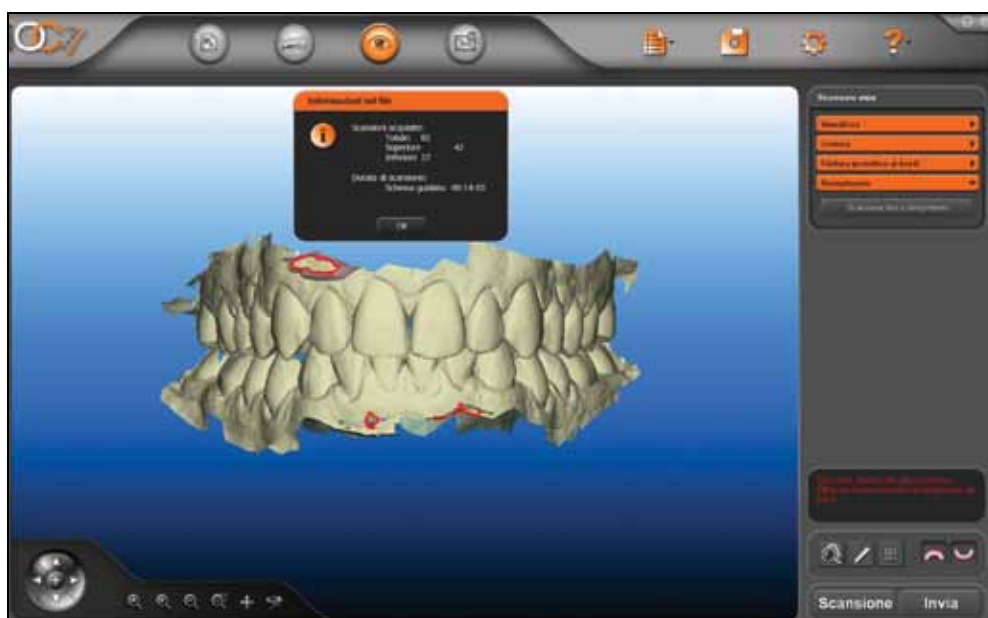

Fig. 4 Intraoral scan for Invisalign patient completed in a little more than 14 minutes.

The iOC software cleans up extraneous elements such as soft tissues, then highlights any areas where further scans are needed to fully capture details of the dentition (Fig. 2). A previous version of the iOC software marked areas of missing details in blue; current software outlines the areas with red circles (Fig. 3). The usual time required for an intraoral scan, after a short learning curve, is about 10 minutes; additional scans, sometimes needed for Invisalign patients, will bring the total scanning time up to 14-15 minutes (Fig. 4). We use the same scanning procedure in non-Invisalign patients—for example, to produce a virtual setup for indirect bonding—except that rescanning is not required in these cases.

Once the scanning is complete, the software produces iRecords (the initial “horseshoe” models) or iCasts (the standard Tweed models in digital form). The clinician can begin preparing the treatment plan within 15 minutes, using a secure website, in the same way as with PVS impressions. The first ClinCheck is usually received within 48 hours, sometimes even 24 hours, after the intraoral scan is submitted. In comparison, a ClinCheck prepared from PVS impressions can take seven to 10 business days.

Discussion

Our Invisalign patients are scanned before treatment and, if needed, for midcourse corrections or case refinement. Scans are also made for Vivera** retainers in both Invisalign and non-Invisalign cases. Ideally, any bonded attachments should be removed before scanning.

We have noticed no difference between the aligners produced from PVS impressions and the aligners produced from intraoral scans in terms of quality, durability, or function. The amounts of sequential molar and premolar movements seen in Class II patients (Figs. 5,6) or of simultaneous tooth movements in Class I cases (Figs. 7,8) have been virtually indistinguishable.

Integration of iOC scanning procedures with

Invisalign technology has demonstrated the following advantages:

- Scanned data offer a reliable and predictable alternative to traditional PVS impressions in Invisalign cases.
- An iRecord is available to the orthodontist almost as soon as the first intraoral scan is taken.
- The iOC software automatically and immediately informs the operator of areas requiring additional scanning data, as opposed to the time-consuming conventional protocol of asking the patient to return for another PVS impression.
- Staff time is saved by eliminating all procedures related to taking, packing, and shipping PVS impressions.
- Less doctor time is spent in online evaluation of various ClinCheck setups.
- The doctor receives the first ClinCheck much sooner, sometimes within 24 hours of scanning; consequently, the aligners are received sooner, allowing an earlier start for the patient.⁷

Since we began using intraoral scans for Invisalign cases, we no longer use PVS impressions in our practice. We are looking forward to further developments in both technologies.

REFERENCES

1. Garino, F. and Garino, G.B.: The OrthoCAD intraoral scanner: A six-month user report, *J. Clin. Orthod.* 45:161-164, 2011.
2. Redmond, W.R. and Redmond, M.J.: Clinical implication of digital orthodontics, *Am. J. Orthod.* 117:240-241, 2000.
3. Christensen, G.J.: Will digital impressions eliminate the current problems with conventional impressions? *J. Am. Dent. Assoc.* 139:761-763, 2008.
4. Guarneri, M.P.; Gracco, A.; and Siciliani, G.: Invisalign: State-of-the art, *Mondo Ortod.* 35:95-105, 2010.
5. Garino, F.: Basic principles and clinical application of the Invisalign system, *Mondo Ortod.* 35:55-74, 2010.
6. Sterental, R.: Staging, in *The Invisalign System*, ed. O.C. Tuncay, Quintessence Publishing Co., New Malden, U.K., 2006, pp. 105-115.
7. Crawford, C.: ClinCheck: Overview and preparation, in *The Invisalign System*, ed. O.C. Tuncay, Quintessence Publishing Co., New Malden, U.K., 2006, pp. 99-104.
8. Boyd, R.L.: Review of the diagnostic process, in *The Invisalign System*, ed. O.C. Tuncay, Quintessence Publishing Co., New Malden, U.K., 2006, pp. 223-253.
9. Tuncay, O.C.: Biologic elements of tooth movement, in *The Invisalign System*, ed. O.C. Tuncay, Quintessence Publishing Co., New Malden, U.K., 2006, pp. 163-176.

(continued on next page)

**Registered trademark of Align Technology, San Jose, CA; www.aligntech.com.

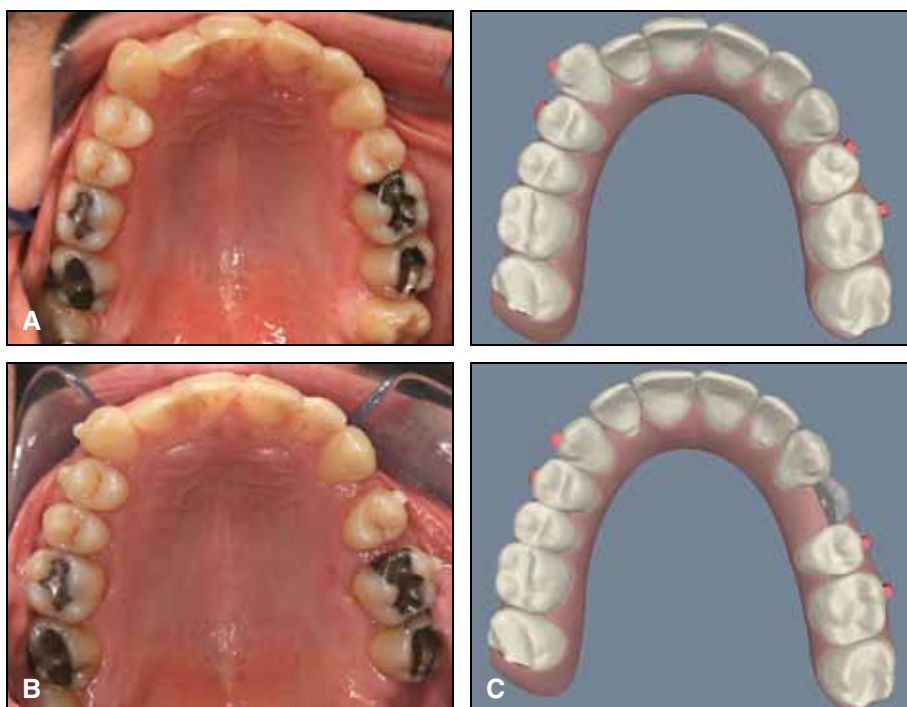


Fig. 5 Sequential tooth movement in Class II, division 1 patient in treatment with aligners fabricated from PVS impressions. A. Pretreatment occlusal photo and ClinCheck. B. Progress after 10 months of distalization. C. Post-treatment ClinCheck projection.

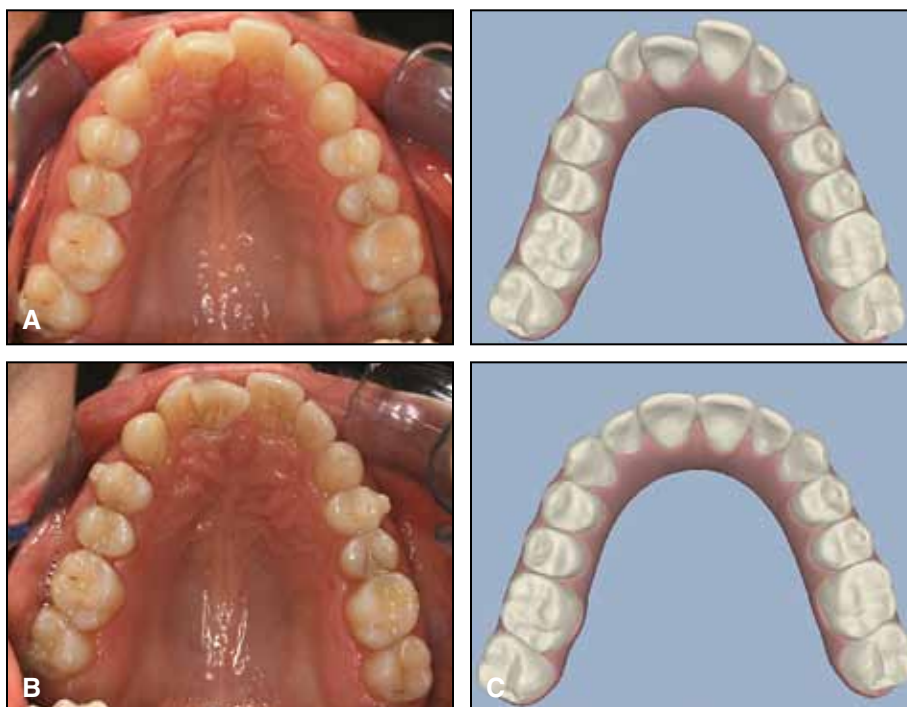


Fig. 6 Sequential tooth movement in Class II, division 1 patient in treatment with aligners fabricated from intraoral scanning data. A. Pretreatment occlusal photo and ClinCheck. B. Progress after 10 months of distalization. C. Post-treatment ClinCheck projection.

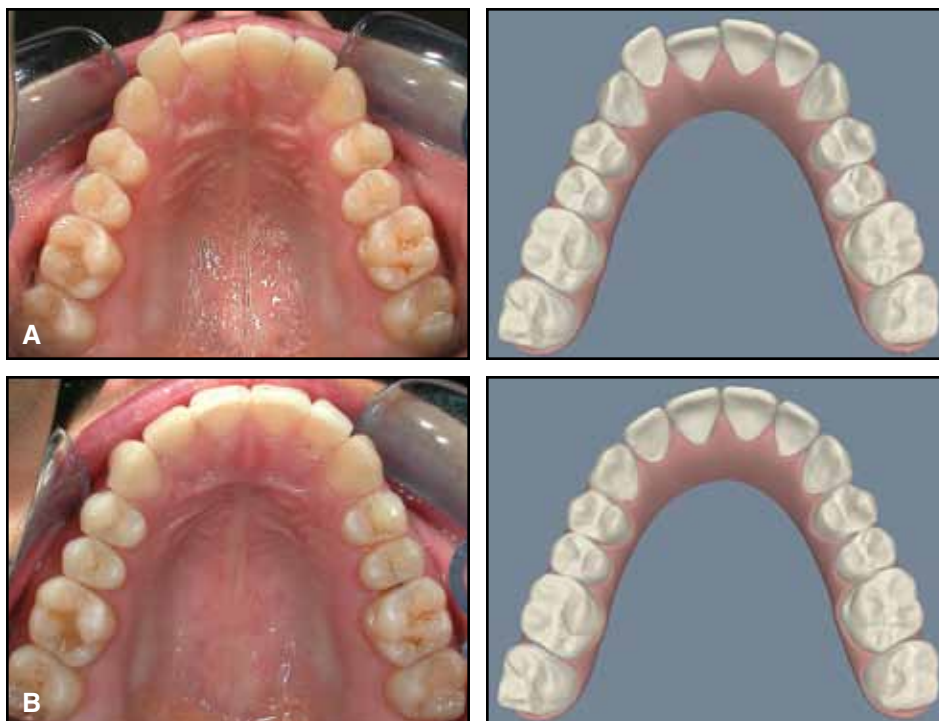


Fig. 7 Simultaneous tooth movement in crowded Class I patient treated with aligners fabricated from PVS impressions. A. Pretreatment occlusal photos and ClinCheck. B. Post-treatment occlusal photo and ClinCheck projection.

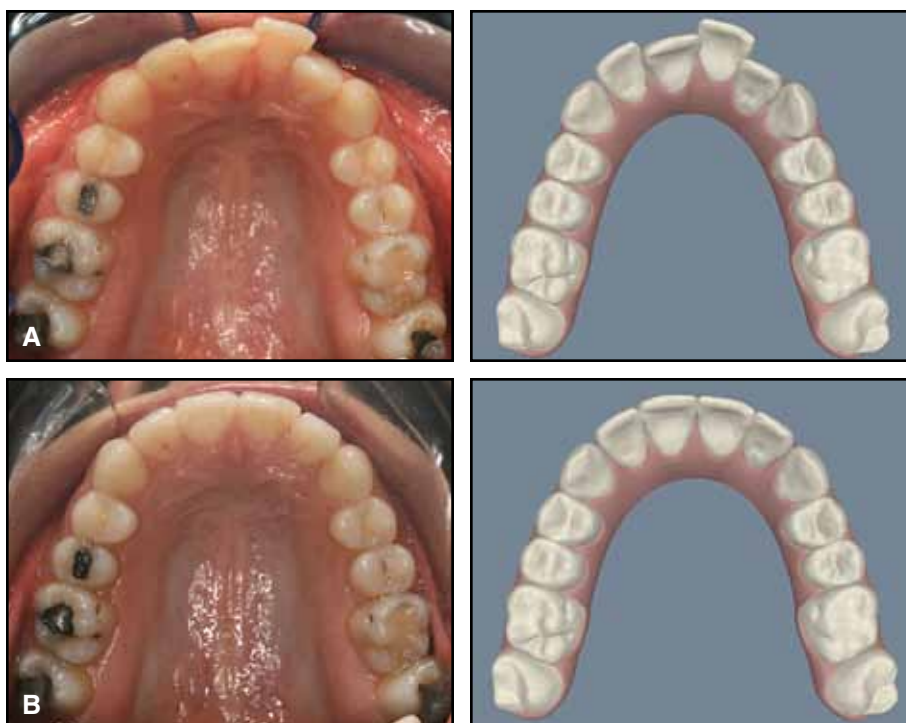


Fig. 8 Simultaneous tooth movement in crowded Class I patient treated with aligners fabricated from intra-oral scanning data. A. Pretreatment occlusal photos and ClinCheck. B. Post-treatment occlusal photo and ClinCheck projection.